

Argon Plasma Coagulation in Barrett's Oesophagus: First Experience from Bangladesh.

Rokshana Begum¹, Ahmed Lutful Moben², Sheikh Mohammad Noor E Alam³, Md. Abdur Rahim⁴, Omar Faruque Sadman⁵, Md. Abdur Rahman⁶, Nasif Shahriar⁷, Nadia Binte Nasir⁸, Nirupoma Das⁹, Taslima Akter Lima¹⁰, Tasnim Mahmud¹¹, Musarrat Mahtab¹², Sheikh Mohammad Fazle Akbar¹³, Mamun Al Mahtab¹⁴

¹Department of Hepatology, Shaheed Suhrawardy Medical College, Dhaka, Bangladesh,

²Kurmitola General Hospital, Dhaka, Bangladesh,

³Department of Hepatology, Bangabandhu Sheikh Mujib Medical University, Dhaka, Bangladesh,

⁴Department of Hepatology, International Medical College, Gazipur, Bangladesh,

⁵Department of Anesthesia, Square Hospital Limited, Dhaka, Bangladesh,

⁶Department of Anesthesia, Analgesia & Intensive Care Medicine, Holy Family Red Crescent Medical College, Dhaka, Bangladesh,

⁷Farabi General Hospital, Dhaka, Bangladesh.

⁸Farabi General Hospital, Dhaka, Bangladesh.

⁹Farabi General Hospital, Dhaka, Bangladesh.

¹⁰Farabi General Hospital, Dhaka, Bangladesh.

¹¹Department of Public Health, North South University, Dhaka, Bangladesh.

¹²Department of Biochemistry, North North South University, Dhaka, Bangladesh.

¹³Ehime University, Ehime, Japan, Oita University, Oita, Japan and Miyakawa Memorial Research Foundation, Tokyo, Japan

¹⁴Interventional Hepatology Division, Bangabandhu Sheikh Mujib Medical University, Dhaka, Bangladesh.

Article Received 27-02-2025 / Article Revised 10-03-2025 / Article Accepted 15-03-2025

ABSTRACT:

Background: Barrett's oesophagus is recognized cause of oesophageal carcinoma. Currently different endoscopic treatment modalities are being adopted and evaluated to manage Barrett's mucosa to prevent subsequent malignant transformation.



This work is licensed under a [Creative Commons Attribution 4.0 International License](https://creativecommons.org/licenses/by/4.0/).

How to Cite

MAMUN AL MAHTAB. Argon Plasma Coagulation in Barrett's Oesophagus: First Experience from Bangladesh. **International Journal of Medical Sciences and Academic Research**, v. 6, n. 02, 19 Mar. 2025.

Methods: We have recently introduced argon plasma coagulation at endoscopy of upper gastrointestinal tract for Barrett's oesophagus management in Bangladesh.

Results: The study included 30 Barrett's oesophagus patients who underwent argon plasma coagulation by a senior Endoscopist. We observed complete eradication of Barrett's oesophagus in 83.3% cases, while reduction of Barrett's mucosal length was seen in 90%.

Conclusion: Argon plasma coagulation appears to be safe and effective for Barrett's oesophagus management. However further work is needed to reach a conclusive statement.

Kew words: oesophagus, Argon Plasma, Coagulation, Barrett's

INTRODUCTIONS:

Barrett's oesophagus is a premalignant condition where oesophageal stratified squamous epithelium undergoes columnar metaplastic transformation progressing to low-grade dysplasia, high-grade dysplasia, which eventually may lead to oesophageal adenocarcinoma[1,2,3]. At the end of 20th century, the incidence of gastroesophageal reflux disease of Barrett's oesophagus was rising alarmingly [4].

With the rise in the incidence of oesophageal cancers[5], the current focus of the management of Barrett's oesophagus has shifted to endoscopic interventions like argon plasma coagulation (APC), radiofrequency ablation (RFA), photodynamic therapy, electrocoagulation, and cryotherapy to manage dysplasia and metaplasia [6,7]. Patients with history of heartburn are 8.3% more prone to developing Barrett's Oesophagus [8].

The basic principle is to destroy Barrett's mucosa and replace it with nonsquamous epithelium. Such procedures are, however, not free from adverse

events, which include stricture and buried gland formation. Not to mention that multiple sessions of interventions are often needed [8, 9, 10].

Due to a lack of clinical studies, the prevalence and risk factors of Barrett's oesophagus in Asian countries are not clear. However, studies reveal that, the prevalence rate is between 0.06% to 43.0% in Asia. Since Barrett's oesophagus is a premalignant condition, its early diagnosis is important to ensure best prognosis [11].

We have recently introduced endoscopic management of Barrett's oesophagus for the first time in Bangladesh with APC.

Materials and Methods:

We included the first 30 patients with Barrett's oesophagus in this study, all of were diagnosed of their pathology at upper gastrointestinal tract endoscopy. All endoscopies were performed by a single, senior Endoscopist with over 27 years of experience of performing more than 50,000 diagnostic and therapeutic endoscopies, including

performing APC for gastric antral vascular ectasia, gastric angiodysplasia, lower gut vascular malformations and debulking of upper and lower gut malignancies. Diagnosis was made on the basis of visual examination of the lower oesophageal epithelium. Follow up endoscopic examinations were performed at 1 to 3 months intervals by the same Endoscopist. We avoided endoscopic biopsies at baseline and during follow up to reduce cost. The Endoscopist's visual diagnosis of Barrett's oesophagus was sufficient.

APC was performed (Fig. 1-3) at a power setting of 55 W, which is 10 W lower than the published literature [10]. Argon gas was supplied at 1.5-1.8 L/min. Each patient underwent single session of APC under total intravascular anesthesia (TIVA) with injection propofol (1mg/kg body weight) administered intravenously by an Anesthetist. Intravenous tiemonium ethyl sulfate injection (5 mg) was applied 15 minutes prior to the procedure to reduce oesophageal spasm in order to ensure precision APC and also to avoid any possible complication. Patients were monitored for minimum 1 hour or till complete recovery from TIVA and allowed to go home subsequently. They were advised to take liquid or semi-solid diet for the next 48 hours and were put on proton pump inhibitor for next 2 months.

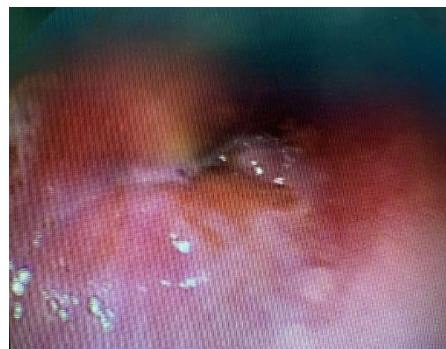

Fig. 1: Endoscopic view of Barrett's oesophagus

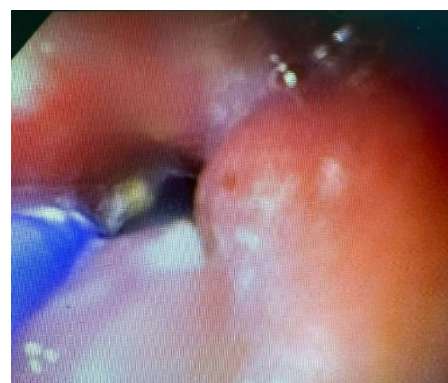


Fig. 2: Endoscopic view of ablation of Barrett's mucosa by APC

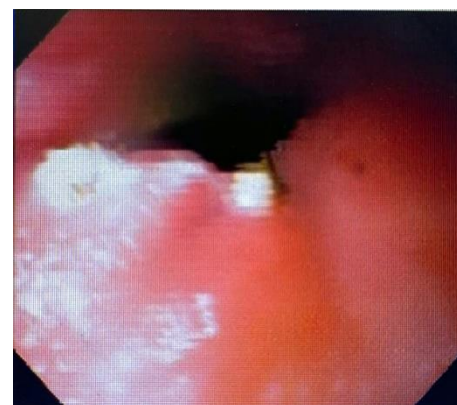

Fig. 3: Endoscopic view of post APC Barrett's oesophagus

Results:

Reduction in the length of Barrett's mucosa was achieved at follow up endoscopy in all 30 patients, with complete eradication in 25 of them. None of the patients developed any serious complication like oesophageal stricture. Out of 30 patients, 12 complained of mild dysphagia and heart burn during the first 1-5 days post-procedure, which resolved with conservative management. However, such complaints did not affect their quality of life and disappeared spontaneously (Table-1).

Discussion:

Endoscopic therapies for Barrett's oesophagus are wide ranging and evolving. A recent meta-analysis has evaluated 7 publications from all over the globe including USA, Russia, Germany, The Netherlands and Australia, but none from our region, as there is paucity of such papers from this part of the world.

In Bangladesh, oesophageal carcinoma is a leading cause of cancer deaths. In 2018, incidence of oesophageal carcinoma was 13.9% and the death rate was 17.9% [13]. Of these, 4.9% were adenocarcinoma [14]. The country lacks facilities and expertise for oesophageal cancer surgeries. There is also a scarcity of Oncologists and advanced radiotherapy centers in the country to treat such a huge burden of oesophageal cancers, like all other cancers. Moreover, most cases present at such a late stage that there is hardly any treatment option that may be offered. Given this harsh reality, our focus has to be on oesophageal

cancer prevention in susceptible cases. The campaign against tobacco has gained momentum and laws have also been adapted prohibiting smoking in public places in Bangladesh. Since, Barrett's oesophagus is an established precondition of oesophageal cancer, endoscopic intervention to eliminate the risk of Barrett's mucosa and thus subsequent possible development of oesophageal cancer has to be taken into consideration.

Although, our experience is limited and also, we are the only centre offering endoscopic APC for Barrett's oesophagus management, our data is indeed encouraging. We documented reduction of Barrett's mucosal length in cent percent cases as well as significant eradication (83.3%). This is at par with previous studies from the advanced West, who have reported 86.4% to 90% complete eradication [15-21]. Another notable aspect of our results is that we experienced no major complication.

APC has its limitations. Although we did not experience any major complication in our series, previous studies have reported from 2.2% to 9.1% oesophageal strictures post-APC [17,21]. Besides, there is also risk of oesophageal perforation, the reason why other endoscopic modalities are also being adopted. To reduce the risk of adverse events, APC is also done reducing power settings, however, this is associated with diminished ablation. Another new approach that has been adopted is called 'fluid cushion' where, before APC sub-mucosal fluid

injection is given into oesophagus to reduce the risk of stricture formation [22]. Although our experience is limited, we feel that in experienced hands, risks of complications of oesophageal APC is mitigated to great extent.

Our study had its limitations. It is a single centre study, where APC was done by a highly experienced Endoscopist, which may have influenced our excellent results. Also we depended on visual inspection by experienced Endoscopist rather than on endoscopic biopsy for baseline and follow up diagnosis and evaluation of Barrett's oesophagus.

Table 1: Patients and outcome

N	30
M:F	21:9
Age	18-65 yrs.
Major complication	none
Heart burn, dysphagia	12
Complete resolution	83.3%
Reduction of Barrett's mucosal length	90%

Conclusion:

From our initial experience we conclude that APC is a safe and effective endoscopic intervention for management of Barrett's oesophagus. However, the procedure must be performed by an experienced therapeutic Endoscopist. Also prospective, long term clinical trial will be needed to conclude that APC is also effective in eliminating the risk of

malignant transformation of Barrett's oesophagus. The durability of non-squamous replacement of Barrett's mucosa is also something that needs to be studied.

References:

1. Burke ZD, Tosh D. Barrett's metaplasia as a paradigm for understanding the development of cancer. *Curr Opin Genet Dev* 2012;22:494-499.
2. Wang DH, Clemons NJ, Miyashita T, et al. Aberrant epithelial-mesenchymal Hedgehog signaling characterizes Barrett's metaplasia. *Gastroenterology* 2010;138:1810-1822.
3. Lagergren J, Lagergren P. Recent developments in esophageal adenocarcinoma. *CA Cancer J Clin* 2013;63:232-248.
4. Runge TM, Abrams JA, Shaheen NJ. Epidemiology of Barrett's esophagus and esophageal adenocarcinoma. *Gastroenterology Clinics of North America*. 2015 Apr 9;44(2):203.
5. Shah SN, Chehade NEH, Tavangar A, Choi A, Monachese M, Chang KJ, Samarasena JB. Hybrid argon plasma coagulation in Barrett's esophagus: a systematic review and meta-analysis. *ClinEndosc*. 2023 Jan;56(1):38-49. doi: 10.5946/ce.2022.179. Epub 2023 Jan 30. PMID: 36733989; PMCID: PMC9902689.
6. Shaheen NJ, Falk GW, Iyer PG, et al. ACG clinical guideline: diagnosis and management of Barrett's esophagus. *Am J Gastroenterol* 2016;111:30-50.

7. Kolb JM, Wani S. Endoscopic eradication therapy for Barrett's oesophagus: state of the art. *Curr Opin Gastroenterol* 2020;36:351-358.
8. Zagari RM, Fuccio L, Wallander MA, Johansson S, Fiocca R, Casanova S, Farahmand BY, Winchester CC, Roda E, Bazzoli F. Gastro-oesophageal reflux symptoms, oesophagitis and Barrett's oesophagus in the general population: the Loiano–Monghidoro study. *Gut*. 2008 Oct 1;57(10):1354-9.
9. Ganz RA, Utley DS, Stern RA, et al. Complete ablation of esophageal epithelium with a balloon-based bipolar electrode: a phased evaluation in the porcine and in the human esophagus. *Gastrointest Endosc* 2004;60:1002-1010.
10. Dunkin BJ, Martinez J, Bejarano PA, et al. Thin-layer ablation of human esophageal epithelium using a bipolar radiofrequency balloon device. *Surg Endosc* 2006;20:125-130.
11. Sultana S, Sweetey RA, Zhumur M, Islam MA, Jahra FT, Dewan RK. Premalignant and malignant esophageal lesions in Bangladeshi patients - a study in a tertiary care hospital. *Central Medical College Journal*. 2023;7(1):20-5.
12. vanVilsteren FG, Pouw RE, Seewald S, et al. Stepwise radical endoscopic resection versus radiofrequency ablation for Barrett's oesophagus with high-grade dysplasia or early cancer: a multicentre randomised trial. *Gut* 2011;60:765-773.
13. Ragunath K, Krasner N, Raman VS, Haqqani MT, Phillips CJ, Cheung I. Endoscopic ablation of dysplastic Barrett's oesophagus comparing argon plasma coagulation and photodynamic therapy: a randomized prospective trial assessing efficacy and cost-effectiveness. *Scand J Gastroenterol*. 2005 Jul;40(7):750-8. doi: 10.1080/00365520510015737. PMID: 16118910.
14. Global cancer observatory (2019) 'Bangladesh, [online], Available: <https://gco.iarc.fr/today/data/factsheets/populations/50-bangladesh-fact-sheets.pdf>.
15. Shil BC, Islam MA, Nath NC, Ahmed F. Oesophageal carcinoma: trends and risk factors in rural Bangladesh. *Journal of Dhaka Medical College*. 2010;19(1):29-32.
16. Staudenmann DA, Skacel EP, Tsoutsman T, et al. Safety and long-term efficacy of hybrid-argon plasma coagulation for the treatment of Barrett's esophagus: an Australian pilot study (with video). *Int J Gastrointest Interv* 2021;10:128-132.
17. Knabe M, Beyna T, Rösch T, et al. Hybrid APC in combination with resection for the endoscopic treatment of neoplastic Barrett's esophagus: a prospective, multicenter study. *Am J Gastroenterol* 2022;117:110-119.
18. Manner H, May A, Kouti I, et al. Efficacy and safety of hybrid-APC for the ablation of Barrett's esophagus. *Surg Endosc* 2016;30:1364-1370.

19. Rösch T, Manner H, May A, et al. Multicenter feasibility study of combined injection and argon plasma coagulation (Hybrid-APC) in the ablation therapy of neoplastic Barrett esophagus. *GastrointestEndosc* 2017;85(5 Supplement):AB154.
20. Linn B, Mangels-Dick T, Clemens MA, et al. Hybrid argon plasma coagulation and radiofrequency ablation in Barrett's esophagus. *GastrointestEndosc* 2020;91(6 Supplement):AB413.
21. Kashin SV, Kuvaev R, Nadezhin AS, et al. The new hybrid argon plasma coagulation (hybrid APC) for endoscopic ablation of Barrett's esophagus (BE): the results of the pilot trial. *GastrointestEndosc* 2016;83(5 Supplement):AB495.
22. Shimizu T, Samarasena JB, Fortinsky KJ, et al. Benefit, tolerance, and safety of hybrid argon plasma coagulation for treatment of Barrett's esophagus: US pilot study. *EndoscInt Open* 2021;9:E1870-E1876.