

## COMPARATIVE STUDY BETWEEN FUNCTIONAL OUTCOME OF LUMBAR LAMINOPLASTY AND DECOMPRESSIVE LAMINECTOMY FOR MULTILEVEL LUMBAR SPINAL CANAL STENOSIS

**Prof. Dr. Md. Anowarul Islam**

MBBS(Dhaka), MS(Ortho), FICS(USA), Professor, Spine surgery, Dept. of Orthopaedics, Bangabandhu Sheikh Mujib Medical University, Dhaka, Bangladesh.

**Dr. Md. Shohidullah**

**Dr. Sarwar Rahman**

**Dr. Mohsina Khan**

**Dr. Sariful Hasan**

Resident, Dept. of Orthopaedics, Bangabandhu Sheikh Mujib Medical University, Dhaka, Bangladesh.

Article Received 17-06-2020 / Article Accepted 22-07-2020 / Article Published 28-07-2020

### **ABSTRACT:**

**Background:** Abnormal narrowing of the lumbar spinal central canal, lateral recess, foramen and extra foraminal space is called lumbar spinal canal stenosis. Patients present with low back pain with or without radiculopathy and neurological claudication and may need surgical intervention, if conservative treatment fails. Lumbar laminoplasty and decompressive laminectomy are few of the surgical intervention techniques.

**Objectives:** To evaluate and compare the functional outcome of lumbar laminoplasty and decompressive laminectomy for patients with multilevel lumbar spinal canal stenosis.

**Methods:** 60 consecutive patients underwent lumbar laminoplasty and decompressive laminectomy in BSMMU from September 2017 to March 2020. The patients were randomized into two groups: one group for lumbar laminoplasty and another group for decompressive laminectomy. Two patients from each group were dropped out at final follow up. Remaining patients were followed up for 12 months. Outcome were measured by VAS, JOA, ODI score and Modified Macnab's criteria. All the data were compiled and sorted properly and the quantitative data was analyzed statistically by using Statistical Package for Social Science (SPSS-22). The results were expressed as percentage and mean  $\pm$  SD and  $p < 0.05$  was considered as the level of significance.

**Results:** Post-operative mean hospital stay was  $5.57 \pm 0.63$  and  $5.44 \pm 0.70$  days in group A and B respectively. Pre-operative mean VAS score of back pain and leg pain were  $6.86 \pm 0.65$  and  $6.93 \pm 0.81$  which



This work is licensed under a [Creative Commons Attribution 4.0 International License](https://creativecommons.org/licenses/by/4.0/).

### **How to Cite**

PROF. DR. MD. ANOWARUL ISLAM, DR. MD. SHOHIDULLAH, DR. SARWAR RAHMAN, DR. MOHSINA KHAN, DR. SARIFUL HASAN. COMPARATIVE STUDY BETWEEN FUNCTIONAL OUTCOME OF LUMBAR LAMINOPLASTY AND DECOMPRESSIVE LAMINECTOMY FOR MULTILEVEL LUMBAR SPINAL CANAL STENOSIS. **International Journal of Medical Sciences and Academic Research**, v. 1, n. 01, p. Page No. 35-46, 28 Jul. 2020.

were reduced to  $1.04\pm 0.19$  and  $1.11\pm 0.31$  in laminoplasty group where as in laminectomy group, preoperative VAS for back pain and leg pain  $6.96\pm 0.65$  and  $6.89\pm 0.80$ , which reduced to  $1.37\pm 0.56$  and  $1.44\pm 0.58$  respectively at 12 months postoperatively. JOA score significantly increased from  $10.68\pm 1.06$  preoperatively to  $27.57\pm 0.63$  postoperatively in laminoplasty group and from  $10.78\pm 1.01$  preoperatively to  $25.59\pm 1.12$  after 12 months of surgery in laminectomy group. ODI score reduced from  $34.43\pm 2.99$  to  $8.39\pm 1.59$  in laminoplasty group and from  $34.93\pm 2.22$  to  $8.81\pm 1.42$  in laminectomy group. Final outcome according to modified Macnab's criteria, Excellent in 17(60.7%), good in 9(32.1%) and fair in 2(7.2%) patients in laminoplasty group whereas 16(57.1%) were excellent, 9(32.1%) were good and 3(10.7%) were fair in laminectomy group. P value was 0.004.

**Conclusion:** Lumbar laminoplasty and decompressive laminectomy are almost same as effective treatment of patients with multilevel lumbar spinal canal stenosis.

**Keywords:** Lumbar spinal canal stenosis, neurogenic claudication, lumbar laminoplasty, decompressive laminectomy.

## **INTRODUCTION:**

Lumbar spinal canal narrowing is a chronically painful and potentially debilitating condition which affects the elderly population [1]. It is a significant cause of low back pain and one of the main indications for low back surgery in elderly patients in the United States. The neurogenic claudication is an important feature of this disease which is the main cause of mobility impairment and loss of self-dependence among elderly people

[2]. Treatment of lumbar canal stenosis consists of conservative, surgical decompression or surgical decompression along with stabilization which may add instrumentation. Surgery is indicated in patients with progressive intolerable symptoms, rapid neurologic deficit or cauda equina syndrome who do not respond to conservative treatment. Decompression of the neural elements adequately

and maintenance of structural stability are necessary for a good outcome

[3]. There is wide number of surgical techniques described for the treatment of lumbar spinal canal stenosis which includes decompressive laminectomy, laminotomy, laminoplasty and microscopic decompression, sublaminar trimming laminoplasty

[4]. Laminectomy has been the method of choice for thorough lumbar decompression for long time. Arthrodesis with or without instrumentation may be needed in some patients [3].

Following laminectomy, iatrogenic instability sometimes occurs in patients with degenerative or spondylolisthetic spinal stenosis. Furthermore, laminectomy membrane which represents epidural scar in the spinal canal, may result in unfavorable sequale after removal of the laminae [3,5]. For this reason, expansive lumbar laminoplasty was

developed. This operation enlarges the spinal canal with adequate decompression of the spinal nerves as well as it reinforces spinal stability by preserving the posterior spinal structures [6,7].

### **MATERIALS AND METHODS:**

This prospective study was carried out at the Department of Orthopaedic Surgery, BSMMU, Shahbag, Dhaka from September 2017 to March 2020. A total number of 60 patients with multilevel lumbar canal stenosis confirmed by MRI were selected who were above 45 years old and had fair trial of conservative treatment. Patients below 45 years old and having tandem stenosis, spondylolisthesis, infection, tumor or fracture of vertebra were excluded from the study. They were allotted in 2 group: group A patients underwent lumbar laminoplasty and group B patients underwent decompressive laminectomy. 2 patients from group A and 2 patients from group B were dropped out in the final follow up at 12 months. out of 56 patients, 28 were male and 28 were female. Outcome was measured by using visual analogue score (VAS) for back pain and leg pain[8], Japanese Orthopaedic Association (JOA) score [9], Oswestry Disability Index (ODI)[10] and Modified Macnab's criteria [11].

### **Surgical technique**

**Group A:** A vertical posterior midline incision was made over the spinous process between L1 to S1 depending on the involved levels. Paraspinal muscles upto medial half of facet joint was dissected by meticulous subperiosteal dissection

using monopolar diathermy on both side avoiding injury to facet joint capsule. The spinous process, interspinous ligament and infraspinal ligament were preserved carefully. Self-retaining mastoid retractors were placed for better visualization. Operative levels were confirmed by fluoroscopy. Fenestration and foraminotomy were done by removing the ligament flavum in between two lamina of desired level by Kerrison rongeur. Both sides of lamina vertically cut by 2 mm diamond burr then lamina with spinous process separated from pars on both side and it was then pulled 5 mm back, decompressing the affected level and fixed with the pars by 4 or 6 holes mini titanium reconstruction plate and screw. A visual check ensures that there is no persistent nerve root compression. The stability of the construct is tested by manual manipulation. Gel foam was applied over exposed dura and nerve roots. Haemostasis was secured. The wound was closed in layers without negative suction drain.

**Group B:** A vertical posterior midline incision was made over the spinous process between L1 to S1 depending on the involved levels. Paraspinal muscles upto medial half of facet joint was dissected by meticulous subperiosteal dissection using monopolar diathermy on both side avoiding injury to facet joint capsule. The spinous process, interspinous ligament and infraspinal ligament were resected. Fenestration and foraminotomy were done by removing the ligament flavum in between two lamina of desired level. Both sides of lamina vertically cut by diamond burr or Kerrison

rongeur and laminae with spinous processes and ligaments excised. Foraminotomy were performed if needed. Discectomy also performed in case of huge disc. Gel foam was applied over exposed dura and nerve roots. Haemostasis was secured. The wound was closed in layers without negative suction drain.

### Statistical analysis

All the data were compiled and sorted properly and the quantitative data was analyzed statistically by using Statistical Package for Social Science (SPSS-22). The results were expressed as percentage and mean  $\pm$  SD and  $p < 0.05$  was considered as the level of significance. Comparison of continuous variables between the two groups was made with Student's t-tests. Comparison of categorical data between two groups was made with Chi-Square tests.

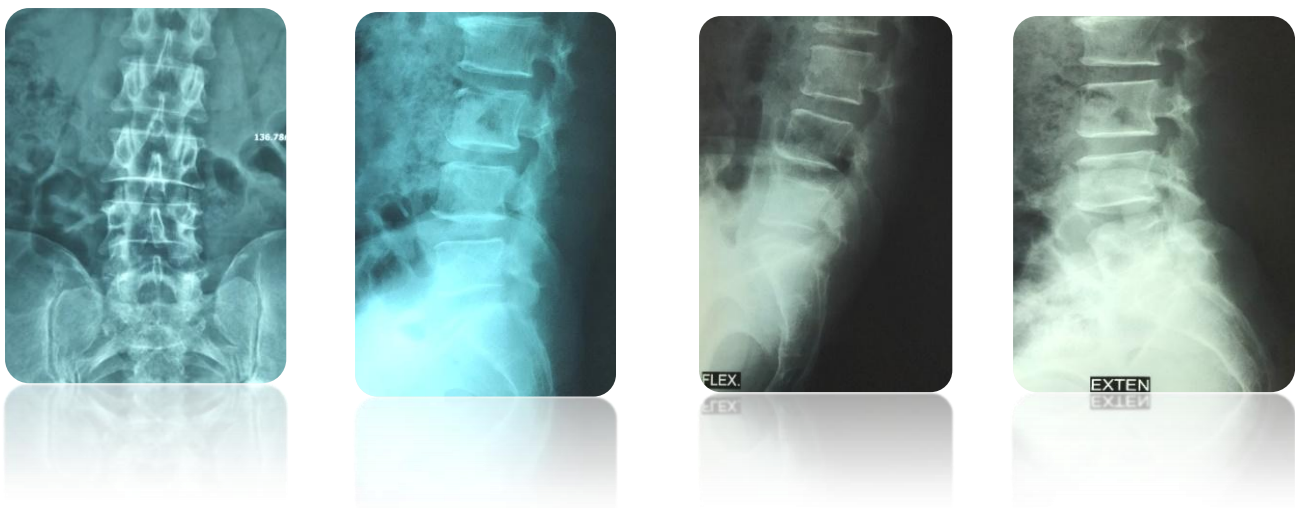


Fig. 1.1: Pre-operative X-ray of lumbosacral spine (A/P, Lateral view and dynamic xray).

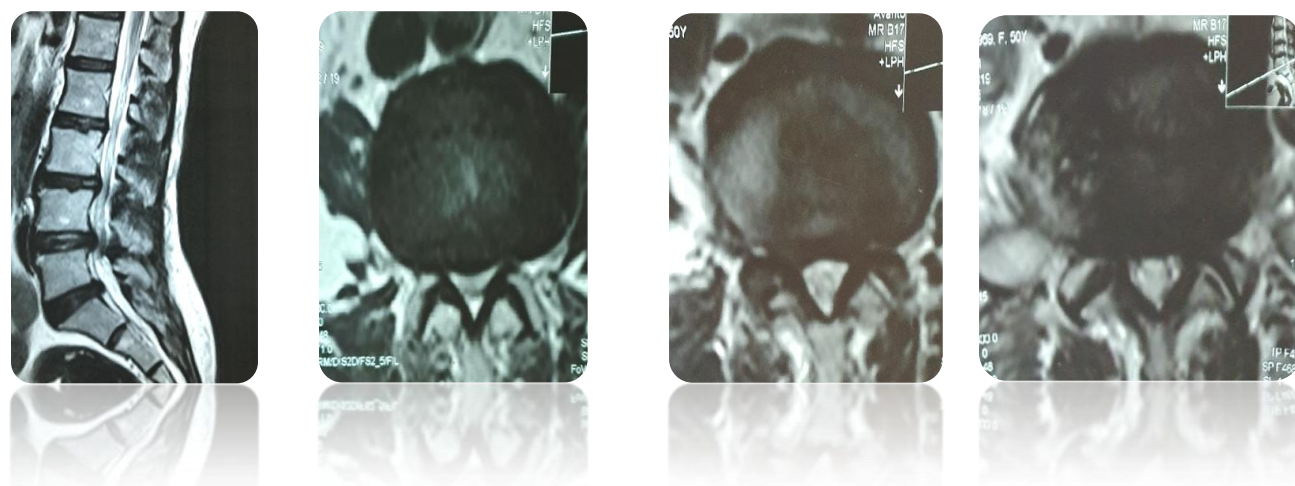


Fig. 1.2: Pre-operative MRI of Lumbosacral spine sagittal and axial section of T2 weighted image

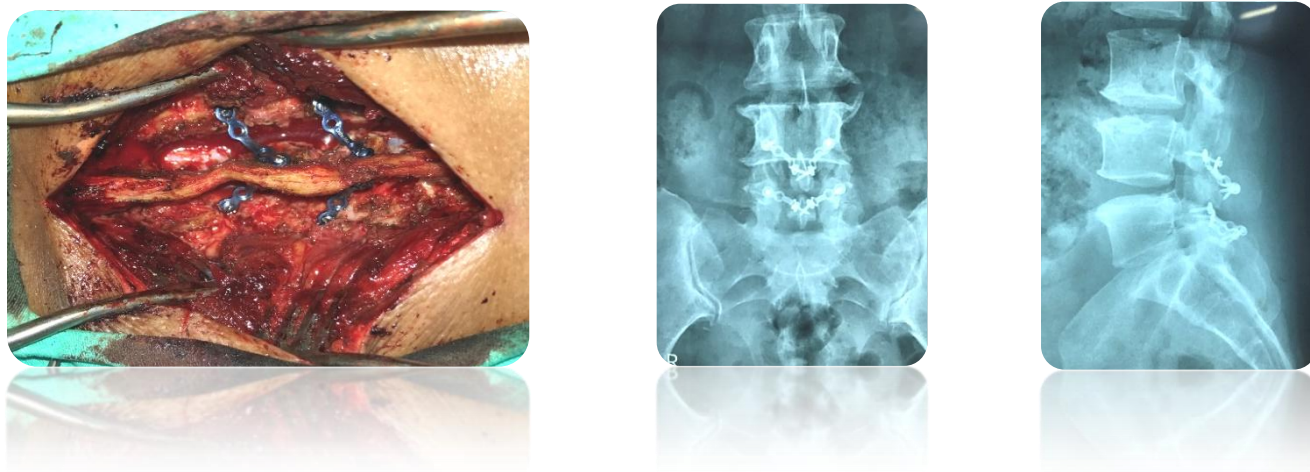


Fig.1.3: Per-operative imaging showing laminoplasty with plate and screws placement and postoperative x-ray.

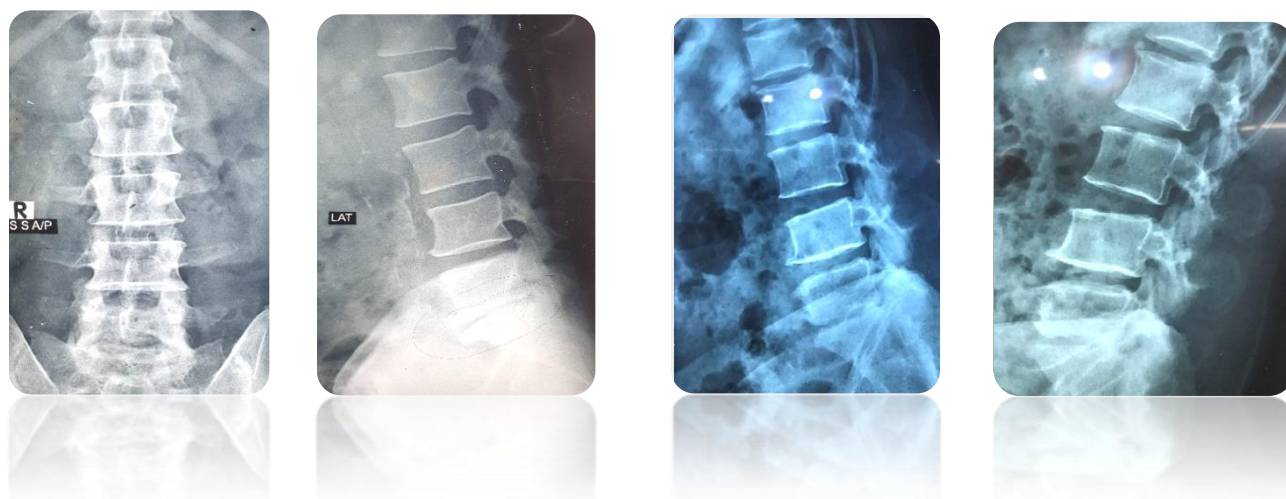


Fig. 2.1: Pre-operative X-ray of lumbosacral spine A/P, Lateral view and dynamic xray.

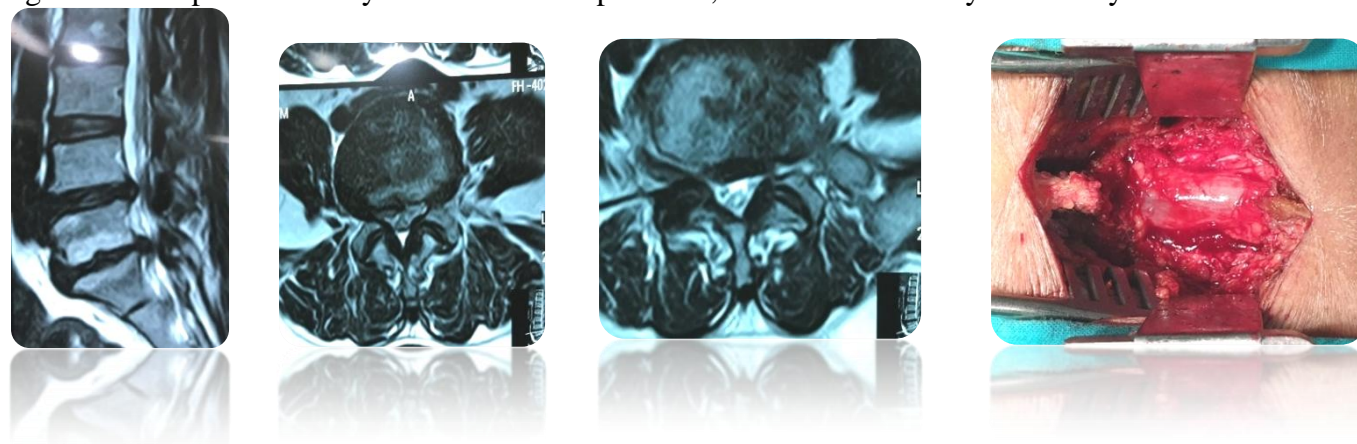


Fig. 2.2: Pre-operative MRI of lumbosacral spine sagittal and axial sections T2 weighted image with operative image of the operative site showing L5 laminectomy.

**RESULTS:**

The mean ( $\pm$  SD) age of the patients was  $56.29 \pm 8.13$  and  $58.15 \pm 5.35$  in group A and B respectively and the youngest and the oldest patients in group A were 46 and 70 years respectively and in group B it is 45 and 66 respectively. Common age group in both group is 51-60 years.

Out of 56 patients, 8 (26.6%) and 7 (25.0%) patients experienced low back pain only, 9 (32.1%) and 12 (42.9%) patients experienced radiculopathy only and 11 (39.3%) and 9 (32.1%) patients experienced both low back pain and radiculopathy in group A and B respectively. Regarding neurological involvement, 23 (82.1%) and 20 (71.4%) patients had sensory involvement, 18 (64.3%) and 14 (50.0%) patients had motor involvement, 9 (32.1%) and 8 (28.6%) patients had diminished jerks (knee or ankle or both) in group A and B respectively. 25 (89.3%) and 22 (78.6%) patients had experienced neurological claudication in group A or B respectively.

Single level surgery was done in 8 (28.6%) and 12 (42.8%) patients, two level surgery was done in 17 (60.7%) and 15 (53.6%) patients and three level surgery was done in 3 (10.7%) and 1 (3.6%) patients in group A and B respectively. So, the highest number of patients had three level involvements in both groups, where two level surgeries were done.

Only one patient in each group had dural tear during operation. Postoperative superficial wound infection developed in 1 (3.6%) patients in group B. No superficial wound infection found in group

A. Average post-operative hospital stay was  $5.57 \pm 0.63$  and  $5.44 \pm 0.70$  days in group A and B respectively.

VAS for back pain in group A and B pre-operatively was  $6.86 \pm 0.65$  and  $6.96 \pm 0.65$  respectively which significantly reduced to  $1.04 \pm 0.19$  and  $1.37 \pm 0.56$  respectively 12 months after operation. VAS for leg pain in group A and B pre-operatively was  $6.93 \pm 0.81$  and  $6.89 \pm 0.80$  respectively which significantly reduced to  $1.1 \pm 0.31$  and  $1.44 \pm 0.58$  respectively 12 months after operation.

JOA score in group A and B pre-operatively was  $10.68 \pm 1.061$  and  $10.78 \pm 1.01$  respectively which significantly increased to  $27.57 \pm 0.63$  and  $25.59 \pm 1.12$  respectively 12 months after operation. ODI score in group A and B pre-operatively was  $34.43 \pm 2.99$  and  $34.93 \pm 2.22$  respectively which significantly reduced to  $8.39 \pm 1.59$  and  $8.81 \pm 1.42$  respectively 12 months after operation.

Final outcome was determined by Modified Macnab's criteria. Excellent result found in 17 (60.7%) and 16 (57.1%), good result found in 9 (32.1%) and 9 (32.1%), and Fair result found in

2(7.2%) and 3(10.7%) group A and group B

respectively. So excellent result found in most of the patients in both groups.

**Table I: Distribution of study population according to pre and postoperative back pain of the study subjects according to VAS (N=56)**

VAS (back pain)	Group A (n=28)	Group B (n=28)	p-value
Pre-operative	6.86 ± 0.65	6.96 ± 0.65	0.549
After 3 months of operation	1.95 ± 0.54	1.99 ± 0.62	0.002
After 6 months of operation	1.07 ± 0.26	1.56 ± 0.70	0.001
After 12 months of operation	1.04 ± 0.19	1.37 ± 0.56	0.004

**Table II: Distribution of study population according to pre and postoperative leg pain of the study subjects according to VAS (N=56)**

VAS (Leg pain)	Group A (n=28)	Group B (n=28)	p-value
Preoperative	6.93 ± 0.81	6.89 ± 0.80	0.856
After 3 months of operation	1.85 ± 0.45	1.93 ± 0.65	0.009
After 6 months of operation	1.18 ± 0.39	1.59 ± 0.75	0.012
After 12 months of operation	1.11 ± 0.31	1.44 ± 0.58	0.009

**Table III: Distribution of study population according to pre and postoperative JOA score (N=56)**

JOA	Group A (n=28)	Group B (n=28)	p-value
Preoperative	10.68 ± 1.06 23.54 ± 0.75	10.78 ± 1.01 22.85 ± 0.80	0.724 0.001
After 3 months of operation			
After 6 months of operation	24.64 ± 0.87	23.15 ± 0.82	<0.001
After 12 months of operation	27.57 ± 0.63	25.59 ± 1.12	<0.001

**Table IV: Distribution of study subjects according to pre and post-operative ODI score (N=56)**

ODI	Group A (n=28)	Group B (n=28)	p-value
Preoperative	34.43 ± 2.99	34.93 ± 2.22	0.488
After 3 months of operation	10.15 ± 2.12	10.55 ± 2.22	0.012
After 6 months of operation	8.93 ± 1.88	9.15 ± 1.73	0.012
After 12 months of operation	8.39 ± 1.59	8.81 ± 1.42	0.009

**Table V: Treatment outcome of the study subjects according to Modified Macnab's criteria (N=56)**

Outcome (Macnab)	Group A (n=28)	Group B (n=28)	p-value
Excellent	17 (60.7%)	16 (57.1%)	0.004
Good	9 (32.1%)	9 (32.1%)	
Fair	2(7.2%)	3(10.7%)	

**DISCUSSION:**

The results of current study demonstrate that mean ( $\pm$  SD) age of the patients was  $56.29 \pm 8.13$  in group A and  $58.15 \pm 5.35$  years in group B which is almost similar to other studies. Kawaguchi et al. (2004) found mean age of 52.6 years in their study of laminoplasty[6]. Islam et al. (2018) found mean age of  $56.8 \pm 7.5$  years in a study with 40 patients underwent lumbar laminoplasty[3]. Javid et al. (1998) found mean age of 61.4, Moughalu et al. (2018) found  $53 \pm 9.92$  years mean age in their study of laminectomy[12,16].

Out of 56 patients, 8 (26.6%) and 7 (25.0%) patients experienced low back pain only, 9 (32.1%) and 12 (42.9%) patients experienced radiculopathy only and 11 (39.3%) and 9 (32.1%)

patients experienced both low back pain and radiculopathy, 23 (82.1%) and 20 (71.4%) patients had sensory involvement, 18 (64.3%) and 14 (50.0%) patients had motor involvement, 9(32.1%) and 8(28.6%) patients had diminished jerks (knee or ankle or both) and 25(89.3%) and 22(78.6%) patients had experienced neurological claudication in group A and B respectively. Kim et al. (2017) found low back pain in 48(70.6%) patients, radiating pain in 66(97.1%) patients, neurologic claudication in 32(47.1%) patients, and Weakness in 19(27.9%) patients in a study of 68 patients with lumbar canal stenosis[13].

Single level surgery was done in 8 (28.6%) and 12 (42.8%) patients, two level surgery was done in 17 (60.7%) and 15 (53.6%) patients and three level surgery was done in 3 (10.7%) and 1 (3.6%)



patients in group A and B respectively. Kim et al. (2017) performed single level laminoplasty in 50(73.5%) and double level laminoplasty in 18(26.5%) where as Liu et al. (2014) performed one level laminoplasty in 3(6.1%) patients, two level laminoplasty in 8(16.3%) patients, 3 level laminoplasty in 27(55.1%) patients and four level laminoplasty in 11(22.4%) patients in a study with 49 patients[13,4]. Jakola et al. (2010) performed one level laminectomy in 48%, two level laminectomy in 42% and three level laminectomy in 9% cases with a four level laminectomy in one patient where as Moughalu et al. (2018) performed one level laminectomy in 43.6%, two level in 46.1% and three level in 10.30% cases[12,14].

One patient in each group (3.6% and 3.6%) had dural tear during operation and only one patient in decompressive laminectomy group developed postoperative superficial wound infection. In the study of Islam et al. (2018), per-operative complication was dural tear in 2 cases in laminoplasty procedure. Moughalu et al. (2018) found 23.1% dural tear and 7.7% superficial wound infection where as Jakola et al. (2010) found 9% dural tear and 3% superficial wound infection in their study with laminectomy[3,12,14].

Postoperative hospital stay was  $5.57 \pm 0.63$  and  $5.44 \pm 0.70$  in group A and B respectively. Almost similar result found by Islam et al. (2018), who found postoperative hospital stay of  $5.2 \pm 1.1$  days in lumbar laminoplasty. Kanaan et al. (2015) found

$4.01 \pm 2.73$  mean postoperative hospital stay in their study with laminectomy[3,15].

VAS for back pain in group A and B pre-operatively was  $6.86 \pm 0.65$  and  $6.96 \pm 0.65$  respectively which significantly reduced to  $1.04 \pm 0.19$  and  $1.37 \pm 0.56$  respectively 12 months after operation. VAS for leg pain in group A and B pre-operatively was  $6.93 \pm 0.81$  and  $6.89 \pm 0.80$  respectively which significantly reduced to  $1.11 \pm 0.31$  and  $1.44 \pm 0.58$ . Islam et al. (2018) found postoperative VAS of  $1.0 \pm 0.2$  in laminoplasty group with preoperative VAS  $7.0 \pm 0.7$  [3]. Similar finding also observed in laminoplasty procedure in the study of Kim and Kwon (2017)[13]. Moughalu et al. (2018) found postoperative VAS of  $2.00 \pm 1.41$  in their study of laminectomy with preoperative VAS  $8.26 \pm 1.46$  [12]. Similar finding found by Panagiotis et al. (2006) in their study with decompressive laminectomy where the average preoperative VAS was 7.9 which decreased to 2.7 during the first postoperative year, to 2.6 during the second postoperative year [18].

JOA score in group A and B pre-operatively was  $10.68 \pm 1.061$  and  $10.78 \pm 1.01$  respectively which significantly increased to  $27.57 \pm 0.63$  and  $25.59 \pm 1.12$  respectively 12 months after operation. Islam et al. (2018) found preoperative JOA score of  $8.6 \pm 2.2$  which increased to  $14.8 \pm 0.4$  postoperatively in lumbar laminoplasty [3]. Liu et al. (2014); Kawaguchi et al. (2004) and Matsui et al. (1997) also found almost similar result in laminoplasty group [4,6,19]. Watanabe et al.

(2005) found JOA score improvement from 59.2 preoperatively to 23.9 postoperatively in a study of laminectomy[20].

ODI score in group A and B pre-operatively was  $34.43 \pm 2.99$  and  $34.93 \pm 2.22$  respectively which significantly reduced to  $8.39 \pm 1.59$  and  $8.81 \pm 1.42$  respectively after 12 months of operation. Islam et al. (2018) found preoperative ODI score  $34.4 \pm 3.0$  which improved to  $8 \pm 1.8$  postoperatively in lumbar laminoplasty and Jakola et al. (2010) found preoperative ODI score 44.2 decreased to 27.9 postoperatively in laminectomy[3,14].

Final outcome was determined by Modified Macnab's criteria. Excellent result found in 17(60.7%) and 16 (57.1%), good result found in 9 (32.1%) and 9(32.1%), and Fair result found in

2(7.2%) and 3(10.7%) in group A and group B respectively. No poor result found in any group.

Matsui et al. (1997) found excellent result in 10(37%), good result in 12(44%), fair in 4(15%) and poor result in 1(4%) patients in their study in 27 patients who underwent lumbar laminoplasty[19]. Fu et al. (2008) found good to excellent result in 89% (68/76) of the patients, fair in 11% (8/76), and poor in 0% patients in group A and good to excellent in 63% (48/76) of the patients, fair in 30% (23/76), and poor in 7% (5/76) patients in group B in their study [21].

### **CONCLUSIONS:**

After analyzing the results of present study, it can be concluded that lumbar laminoplasty and decompressive laminectomy are almost same as

effective treatment of patients with multilevel lumbar spinal canal stenosis.

### **Ethical Issue**

Informed written was taken from the patient. Confidentiality, privacy of the patient ensured with respect and responsibility.

### **Reference:**

1. Park DK, An HS, Lurie JD, Zhao W, Tosteson A, Tosteson TD, Herkowitz H, Errico T, Weinstein JN. Does Multilevel Lumbar Stenosis Lead to Poorer Outcomes? A Subanalysis of the Spine Patient Outcomes Research Trial (SPORT) Lumbar Stenosis Study. *SPINE* 2010; 35 (4):439–446.
2. Turner JA, Ersek M, Herron L, Deyo R. Surgery for Lumbar Spinal Stenosis: Attempted Meta-Analysis of the Literature. *SPINE* 1992; 17(1):1-8.
3. Islam MA, Shrestha M, Batajoo S, Mishra D. Evaluation of result of lumbar laminoplasty for multilevel lumbar canal stenosis. *Bangabandhu Sheikh Mujib Medical University Journal* 2018;11:218-221.
4. Liu WJ, Hong SW, Liou SY, Lu TW. Clinical outcomes following sublaminar-trimming laminoplasty for extensive lumbar canal stenosis. *European Spine Journal* 2014; 23:80-86.

5. Omidi-Kashani F, Hasankhani EG, Rahimi MD, Golshani V. Laminotomy Versus Laminectomy in Surgical Treatment of Multilevel Lumbar Spinal Stenosis in Patients More Than 65 Years Old. *Global Journal of Surgery* 2014; 2(1):7-11
6. Kawaguchi Y, Kanamori M, Ishihara H, Kikkawa T, Matsui H, Tsuji H, Kimaru T. Clinical and Radiographic Results of Expansive Lumbar Laminoplasty in Patients with Spinal Stenosis, *The Journal of Bone and Joint Surgery* 2004; 86:1698-1703.
7. Kawaguchi Y, Kanamori M, Ishihara H, Kikkawa T, Matsui H, Tsuji H, Kimaru T. Clinical and radiographic results of expansive lumbar laminoplasty in patients with spinal stenosis- Surgical technique. *The Journal of Bone and Joint Surgery* 2005; 86(I):292-299.
8. VonKorff M, Deyo RA, Cherkin D, Barlow W. Backpain in primary care: outcome at 1 year. *SPINE* 1993;18(7):855-862.
9. El Shazly AA, El Wardany MA, Morsi AM. Recurrent lumbar disc herniation: A prospective comparative study of three surgical management procedures. *Asian Journal of Neurosurgery* 2013;8(3):139-146.
10. Fairbank JCT, Pynsent PB. The Oswestry Disability Index. *Spine* 2000; 25(20):2940-2953.
11. Macnab I. Negative Disc Exploration: An Analysis of the Cause of Nerve Root Involvement in Sixty-eight Patients. *Journal of Bone and Joint Surgery* 1971; 53-A(5):891-903.
12. Muoghalu ON, Nwadinigwe CU, Iyidobi EC, Duru NN, Anyaehie UE, Okwesili IC. Early Functional Outcome of Posterior Spinal Decompression for Lumbar Spinal Stenosis at a Tertiary Health Institution, South East Nigeria. *Journal of Biosciences and Medicines* 2018; 6:1-14.
13. Kim JH, Kwon YJ. Long-term Clinical and Radiological Outcomes after Central Decompressive Laminoplasty for Lumbar Spinal Stenosis. *Korean Journal of Spine* 2017;14(3):71-76.
14. Jakola AS, Sorlie A, Gulati S, Nygaard OP, Lydersen S, Solberg T. Clinical outcomes and safety assessment in elderly patients undergoing decompressive laminectomy for lumbar spinal stenosis: A prospective study. *BMC Surgery* 2010;10:34.
15. Kanaan SF, Waitman LR, Yeh HW, Arnold PM, Burton DC, Sharma NK. Structural equation model analysis of the length-of-hospital stay after lumbar spine

- surgery. *The Spine Journal* 2015;15(4):612-621.
16. Javid MJ, Hadar EJ. Long-term follow-up review of patients who underwent laminectomy for lumbar stenosis: A prospective study. *Neurosurgical Focus* 1998;4(5):1-7.
17. Kalichman L, Cole R, Kim DH, Li L, Suri P, Guermazi A, Hunter DJ. Spinal stenosis prevalence and association with symptoms: the Framingham Study. *The Spine Journal* 2009; 9(7):545–550.
18. Panagiotis ZE, Athanasios K, Panagiotis D, Minos T, Charis M, Elias L. Functional outcome of surgical treatment for multilevel lumbar spinal stenosis. *Acta orthopaedical* 2006;77(4):670-676.
19. Matsui H, Kanamori M, Ishihara H, Hirano N, Tsuji H. Expansive lumbar laminoplasty for degenerative spinal stenosis in patients below 70 years of age. *European Spine Journal* 1997; 6:191-196.
20. Watanabe K, Hosoya T, Shiraishi T, Matsumoto M, Chiba K, Toyama Y. Lumbar spinous process—splitting laminectomy for lumbar canal stenosis. *Journal of neurosurgery: spine* 2005; 3:405-408.
21. Fu YS, Zeng BF, and Xu JG. Long-term Outcomes of Two Different Decompressive Techniques for Lumbar Spinal Stenosis. *Spine* 2008; 33(5):514-518.