

Celiac disease cure: I just open the door but you must walk through it yourself

Muftah A. Otman¹, Ahmed G. Elsayed², Salah Eldein K. Mohammed³, Saeed H. Ali¹, Nasren G. Saleh Alfrik¹, Khadeejah M. Ali Alkhrum¹, Rihab O. Abdallrazk¹, Khaled E. Omran⁴, Laila M. Elgendy⁵, Awad M. Alhasnony⁵.

¹Faculty of Medicine, Pediatric Department, Tobruk University, Libya.

²Tobruk Medical Center, Pathology Department, Libya.

³Faculty of Medicine, Pathology Department, Tobruk University, Libya.

⁴Faculty of Medicine, Medicine Department, Tobruk University, Libya.

⁵Faculty of Medicine, Biochemistry Department, Tobruk University, Libya.

Article Received 05-06-2020 / Article Revised 10-07-2020 / Article Accepted 15-07-2020

ABSTRACT:

Celiac disease (CD) is an autoimmune condition characterized by a specific serological and histological profile triggered by gluten ingestion in genetically predisposed individuals. Celiac disease (CD) is the most common autoimmune gastrointestinal disease, affecting nearly 1% of the world population. There are currently no US Food and Drug Administration (FDA)-approved treatments, other than a gluten-free diet (GFD). Chemokines have been widely related to autoimmunity and inflammation, due to their key role in the selective recruitment of leukocytes. CX3CL1 can be found as a membrane-attached protein acting as an adhesion molecule, or as a soluble protein with chemo tactic properties.

Aim of the work: To study the prevalence and clinical significance of CX3CL1 expression and its association with clinicopathological features of Celiac disease (CD) in Tobruk-Libya

Patients, Materials and Methods: The study group included 29 selected cases of Celiac disease, diagnosed at Pathology department of Tobruk Medical Center, Libya, between 2016 and 2019. All patients were underwent upper gastrointestinal endoscopy with biopsy intake. Other clinicopathological data (gender, age, intestinal and extra-intestinal manifestations) were extracted from medical files. All cases are stained with Hematoxylin and eosin stains and immunohistochemistry for CX3CL1.

Results: The details of 29 patients selected for analyses are as follows. The mean age of the patients at time of endoscopy biopsy was 111 months (range, 6–216 months, 18 years) with peak age between 6 and 24 months, and 8 were (27.6%) males and 21 (72.4%) were females. 25 cases of the Celiac disease presented by



This work is licensed under a [Creative Commons Attribution 4.0 International License](https://creativecommons.org/licenses/by/4.0/).

How to Cite

SAEED H. ALI¹, NASREN G. SALEH ALFRIK¹, KHADEEJAH M. ALI ALKHRUM¹, M. A. O. A. G. E. S. E. K. M. Celiac disease cure: I just open the door but you must walk through it yourself. *International Journal of Medical Sciences and Academic Research*, v. 1, n. 01, p. 1-9, 16 Jul. 2020.

intestinal manifestations (86.2%) and 4 cases presented by extra-intestinal manifestations (13.8%). Immunohistochemical analysis of CX3CL1 expression was shown in all cases. 27 Celiac disease tissue biopsies (93.1%) showed negative CX3CL1 staining (score 0), while 2 biopsies showed positive CX3CL1 immunostaining 1+ and 2+. Total number of cases which demonstrated overexpression of 2+/3+ were 24 (16.9%).

Conclusion: CX3CL1 can be used as diagnostic marker useful for Celiac disease (CD). Further larger researches are compulsory to validate CX3CL1 as an alternative therapeutic target in Celiac disease.

Keywords: Celiac disease; Cure; CX3CL1; Immunohistochemistry (IHC).

INTERODUCTION:

Celiac disease (CD) is an autoimmune disease characterized by a specific serological and histological profile triggered by the ingestion of gluten in genetically predisposed children. Gluten is the general term for alcohol-soluble proteins present in various cereals, including wheat, rye, barley, spelt, and kamut [1].

Current guidelines for the management of CD specify lifelong adherence to a strict gluten-free diet [2,3]. For most of the children with celiac disease, strict avoidance of gluten is the only treatment proven to produce clinical, serologic, and histologic improvement [4,5].

Celiac disease (CD) is the most common autoimmune gastrointestinal disease, affecting ~1% of the world population. There are currently no US Food and Drug Administration (FDA)–approved treatments, other than a gluten-free diet (GFD) [6].

The current diagnosis is based on demonstrating the enteropathy in small intestinal biopsies where histologic examination shows villous atrophy, crypt hyperplasia, and intraepithelial lymphocytosis, and the presence of circulating Celiac disease-specific antibodies to tissue transglutaminase (tTG), deamidated gliadin peptides (DGP), and endomysium (EMA) [7].

The clinical manifestation is broad and includes gastrointestinal disturbances, chronic fatigue, nutrient deficiencies, poor growth, and lastly failure to thrive Extra-intestinal manifestations are

Common, and while they were once considered more frequent in adults than children with CD, recent data suggests the frequency is similar in CD children, although the types and rates of recovery differ [8].

In children, extra-intestinal manifestations include anemia, short stature, delayed puberty, dental enamel hypoplasia, reduced bone density, oral ulcers, liver and biliary disease, and dermatitis herpetiformis. Poor growth and anemia appear to be the most common and there is a correlation with more severe histological damage at diagnosis compared to children with a gastrointestinal presentation or screen-detected cases [9].

Chemokines have been widely related to autoimmunity and inflammation, due to their main role in the selective recruitment of leukocytes. CX3CL1, also named fractalkine, constitutes a particular chemokine, which is the only member of a family that presents three amino acids between the first two cysteine residues in its primary structure. It is also remarkable that its mature form appears as a transmembrane protein that can be cleaved, resulting in a soluble form. Therefore, CX3CL1 can be found as a membrane-attached protein acting as an adhesion molecule, or as a soluble protein with chemotactic properties

[10,11]. Some authors have related these proteins to coeliac disease (CD) [12,13,14].

Due to increased incidence of Celiac disease in Tobruk, Libya, we were able to collect a cohort of 29 Celiac disease patients with duodenal biopsies and follow up information. In this project we utilized this patient collection to investigate prevalence and clinical significance of CX3CL1 expression in Celiac disease as It has not been thoroughly studied in Tobruk, Libya population.

Patients, Materials and Methods:

The present study is a retrospective study.

The study group included 29 selected cases of Celiac disease, diagnosed at Pathology department of Tobruk Medical Center, Libya, between 2016 and 2019. All patients were underwent upper gastrointestinal endoscopy with biopsy intake. The selection process was based on the histological criteria for diagnosis of Celiac disease. Other clinicopathological data (gender, age, intestinal and extra-intestinal manifestations) were extracted from medical files. Five tissue specimen of normal duodenal tissue were added in the study to compare CX3CL1 expression.

Processing Procedures:

For each case, a representative paraffin-embedded tissue was chosen.

The paraffin wax sections were cut at 4 microns and stained by:

- a. Hematoxylin and eosin stain for routine histopathological examination.
- b. Immunohistochemical staining by CX3CL1 monoclonal antibodies.

Each case of Celiac disease was studied for histopathological diagnosis.

Each section obtained from the blocks was placed on positive charge slides, dewaxed in xylene,

rehydrated in consecutive descending concentrations of ethanol (100%, 90%, 80%, and 70%), and rinsed in distilled water.

For antigen retrieval, slides were placed in a plastic container filled with sufficient citrate buffer pH 6 and heated in a microwave oven at 100°C for three successive times, five minutes each. The amount of fluid in the container was checked and was added if necessary to prevent slides from drying out.

The slides were immersed in 3% hydrogen peroxide for 10 minutes to block endogenous peroxidase, and incubated with the primary antibody for CX3CL1 (rabbit monoclonal, Thermo Scientific), at 1:100 dilution, overnight, at 40C. Chromogen application by using DAB (3,3-diaminobenzidine tetrahydrochloride). The counterstaining of the sections was done with Mayer's Hematoxylin. Fibroblasts, known to express CX3CL1, were used as the positive control in order to verify the accuracy of the technique.

CX3CL1 immunostaining reactions were recognized as homogenous cytoplasmic expression.

Briefly, Celiac disease were categorized into four groups based on intensity score (0, 1+, 2+, 3+). Intensity score 1+, 2+ and 3+ was taken as positive

Statistical Analysis:

The collected data were coded then entered and analyzed using the SPSS version 22 (Statistical package for social science).

Descriptive statistics was done for categorical variables by frequency and percentage, and for numerical variables in the form of mean and standard deviation (mean \pm SD).

Suitable statistical tests of significance were used:

- Chi-Square (χ^2) test for categorical data

P-values equal to or less than 0.05 were considered statistically significant

RESULT:

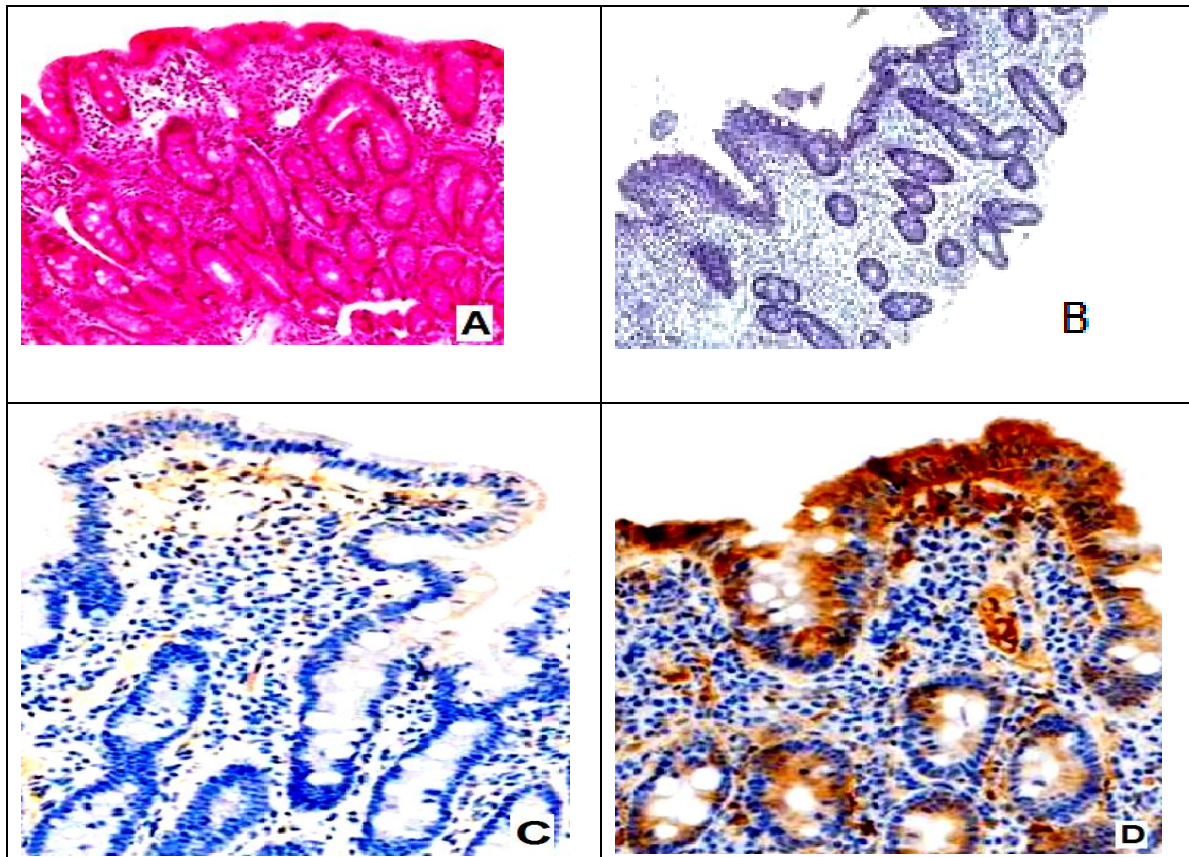
Clinicopathological Features:

The details of 29 patients selected for analyses are as follows. The mean age of the patients at time of endoscopy biopsy was 111 months (range, 6–216 months, 18 years) with peak age 24 cases (82.8%) between 6 and 24 months, and 8 were (27.6%) males and 21 (72.4%) were females, female : male (2.6:1). 25 cases of the Celiac disease presented by intestinal manifestations (86.2%) and 4 cases presented by extra-intestinal manifestations (13.8%).

CX3CL1 expression:

Immunohistochemical analysis of CX3CL1 expression was shown in all cases. 27 Celiac disease tissue biopsies (93.1%) showed negative CX3CL1 staining (score 0), while 2 biopsies showed positive CX3CL1 immunostaining 1+ and 2+. Total number of cases which demonstrated overexpression of 2+/3+ were 24 (16.9%) (Figure 1).

Immunohistochemical analysis of CX3CL1 expression was positive in normal duodenal epithelial cells.



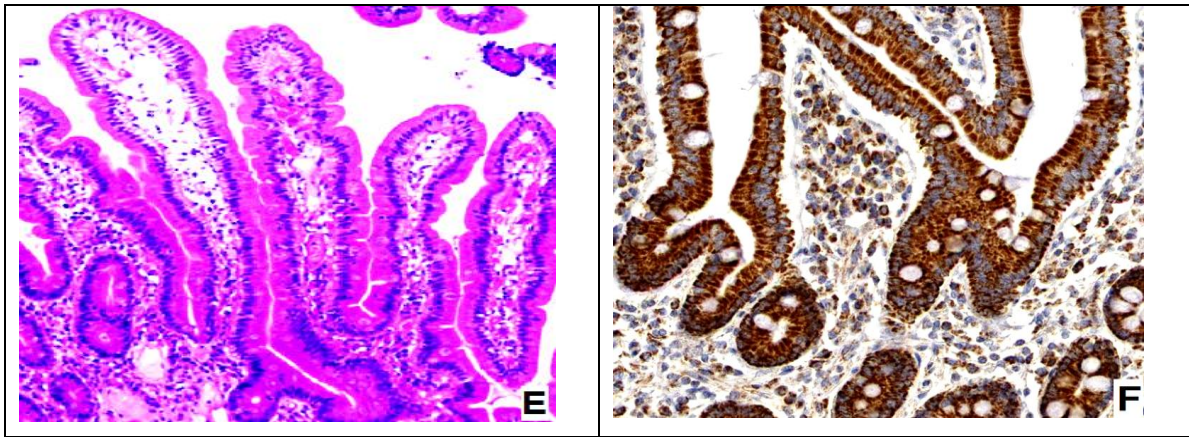


Figure (1): A- Celiac disease (H&E 40x), B- Negative CX3CL1 expression in Celiac disease (CX3CL1 40x), C- Positive CX3CL1 expression in Celiac disease (1+) (CX3CL1 100x), D- Positive CX3CL1 expression in Celiac disease (2+) (CX3CL1 100x), E- Normal duodenal epithelium (H&E 40x), and F- Positive CX3CL1 expression in normal duodenal epithelium (3+) (CX3CL1 100x),.

Correlations between CX3CL1 expression and clinicopathological features:

Univariate analysis revealed no significant correlation between CX3CL1 expression (negative versus positive) and age, gender as well as intestinal and extra-intestinal manifestations (Table 1).

Clinicopathological characteristics	CX3CL1 expression		Chi-square test
	Negative 27	Positive 2	
Age at time of endoscopy biopsy (median)			
< 111 months (20 cases)	19 (95%)	1 (5%)	P=0.548
≥ 111 months (9 cases)	8 (88.9%)	1 (11.1%)	
Gender			
Males (8 cases)	7 (87.5%)	1 (12.5%)	P=0.462
Females (21 cases)	20 (95.2%)	1 (4.8%)	
Presented manifestations			
Intestinal (25 cases)	24 (96%)	1 (4%)	P=0.124
Extra-Intestinal (4 cases)	3 (75%)	1 (25%)	

p-value <0.05 was considered to be statistically significant.

Table (1): Relationship between CX3CL1 expression and clinicopathological characteristics.

DIACUSSION:

The CX3CL1–CX3CR1 axis has been related to numerous diseases, including several autoimmune disorders [15,16,17]. It has even been proposed as a potential biomarker and therapeutic target [18,19,20]. Therefore, we investigated the possible role of CX3CL1 in Celiac disease.

Females predominated was clear in the present study with the male-female-male ratio of (2.6:1). This was similar to the gender ratio ranging from (2 :1) (2.8: 1) as reported by two studies Hin H., et al. [21] and Gujral N., et al. [22] respectively, and also agreed with Singh P., et al. that said the female to male ratio (2.2:1) [23].

Our study shows that 82.8% of cases diagnosed as celiac disease occur in between 6 months and 24

months of life which consider as the peak age of incidence; this comes into agreement with Walker-Smith JA., et al. [24] Catharsis C., et al. [25] and Dietrich W., et al. [26] that conducts studies showing almost same finding with peak age of diagnosis of celiac disease in children from 6 to 24 months.

Intestinal manifestation (86.2%) more commonly begins to appear weeks to a few months after the weaning has been started while extra intestinal manifestation (13.8%) appears later on which are concomitant with the study conducted by Dieterich W., et al. [26] that shows the same result.

The clinicopathological characteristics and CX3CL1 expression relationship in our results shows no significant association with age, gender, or intestinal and extra-intestinal manifestations.

We have observed CX3CL1 expression in epithelial and endothelial cells in the small intestine.

An important finding is the occasional presence of CX3CL1 in the duodenal epithelium of Celiac disease patients. Further studies on wide scale is needed for confirmation our results, but our results introduce new method for Celiac disease diagnosis.

Immunohistochemistry is widely used in clinical diagnosis, and duodenal biopsies are required when testing for Celiac disease in adults and in children with uncertain diagnosis. Therefore,

CONCLUSION:

Our results show the potential of CX3CL1 involvement in appearance and progression of

CX3CL1 is considered a possible method that can diagnose Celiac disease without additional sampling.

Epithelial cells have been described as the source of soluble CX3CL1 and the other studied chemokines [13,27,28], which would create a gradient to direct lymphocyte migration to the intestinal mucosa.

Lack of CX3CL1 in the epithelium of Celiac disease patients could be caused by its cleavage into the soluble form, which may be hard to distinguish by immunohistochemistry, and it would then act as a chemoattractant [29].

Role of CX3CL1 is recruiting inflammatory cells to the target tissue and initiating and propagating inflammation and disease. In this respect, its potential use as a biomarker and therapeutic target has been studied under numerous conditions [29]. Unfortunately, there is no much studies to discuss with these results.

Limitations of the study:

Our study has some limitations. First, a small sample size was used to identify the value of CX3CL1 expression in Celiac disease because of the short study period. Second, there are no established criteria to describe the degree of CX3CL1 staining. Third, there is no follow-up of the patients, and this study is designed and performed recently.

Celiac disease, and it appears to be a potential diagnostic biomarker.

Definitely, we are attentive that further, larger researches are compulsory to validate CX3CL1 as an alternative therapeutic target in Celiac disease.

REFERENCES:

1. Giacomo Caio, Umberto Volta, Anna Sapone, Daniel A. Leffler, Roberto De Giorgio, Carlo Catassi & Alessio Fasano, Celiac disease: a comprehensive current review, *BMC Medicine* volume 17, Article number: 142 (2019).
2. Rubio-Tapia A, Hill ID, Kelly CP, et al. American College of Gastroenterology. ACG guidelines: diagnosis and management of celiac disease. *Am J Gastroenterol.* 2013;108:656–676.
3. Ludvigsson JF, Bai JC, Biagi F, et al. BSG Coeliac Disease Guidelines Development Group; British Society of Gastroenterology. Diagnosis and management of adult coeliac disease: guidelines from the British Society of Gastroenterology. *Gut.* 2014;64:1210–1228.
4. Hornell A. Effects of a gluten-free diet on gastrointestinal symptoms in celiac disease. *Am J Clin Nutr.* 2007;85:160–166.
5. Catassi C, Fabiani E, Iacono G, et al. A prospective, double-blind, placebo-controlled trial to establish a safe gluten threshold for patients with celiac disease. *Am J Clin Nutr.* 2007;85:160–166.
6. Ciarán P Kelly, Matthew A Dickason, Angel Cebolla Ramirez, Francisco Leon, Remedios Dominguez, Jennifer A Sealey-Voyksner, Determination of gluten consumption in celiac disease patients on a gluten-free diet, *The American Journal of Clinical Nutrition*, Volume 107, Issue 2, February 2018, Pages 201-207.
7. Husby S, Koletzko S, Korponay-Szabo IR, Mearin ML, Phillips A, Shamir R, et al. European society for pediatric gastroenterology, hepatology, nutrition guidelines for the diagnosis of coeliac disease. *J Pediatr Gastroenterol Nutr.* 2012;54:136–60.
8. Jericho H, Guandalini S. Extra-intestinal manifestation of celiac disease in children. *Nutrients* 2018;10:755.
9. Nurminen S, Kivela L, Huhtala H, Kaukinen K, Kurppa K. Extraintestinal manifestations were common in children with coeliac disease and were more prevalent in patients with more severe clinical and histological presentation. *Acta Paediatr.* 2018;107:1-7.
10. Bazan, J.F.; Bacon, K.B.; Hardiman, G.; Wang, W.; Soo, K.; Rossi, D.; Greaves, D.R.; Zlotnik, A.; Schall, T.J. A new class of membrane-bound chemokine with a CX3C motif. *Nature* 1997;385, 640–644.
11. Umehara, H.; Bloom, E.T.; Okazaki, T.; Nagano, Y.; Yoshie, O.; Imai, T. Fractalkine in vascular biology: From basic research to clinical disease. *Arterioscler. Thromb. Vasc. Biol.* 2004;24, 34-40.
12. Garrote, J.; Gómez, E.; León, A.L.; Bernardo, D.; Calvo, C.; Fernández-Salazar, L.; Blanco-Quirós, A.; Arranz, E. Cytokine, Chemokine and Immune Activation Pathway Profiles in Celiac Disease: An Immune System Activity Screening by Expression Macroarrays. *Drug Target Insights* 2008;3, 1-11.
13. Pietz, G.; De, R.; Hedberg, M.; Sjoberg, V.; Sandstrom, O.; Hernell, O.; Hammarstrom, S.; Hammarstrom, M.L. Immunopathology of childhood celiac disease-Key role of intestinal epithelial cells. *PLoS ONE* 2017;12, e0185025.
14. Rezaei Tavirani, M.; Bashash, D.; Tajik Rostami, F.; Rezaei Tavirani, S.; Nikzamir, A.; Rezaei Tavirani, M.; Haidary, M.H. Celiac disease microarray

- analysis based on System Biology Approach. *Gastroenterol. Hepatol. Bed Bench* 2018;11, 216-224.
15. Liu, W.; Jiang, L.; Bian, C.; Liang, Y.; Xing, R.; Yishakea, M.; Dong, J. Role of CX3CL1 in Diseases. *Arch. Immunol. Ther. Exp.* 2016, 64, 371–383.
 16. Imgenberg-Kreuz, J.; Sandling, J.K.; Bjork, A.; Nordlund, J.; Kvarnstrom, M.; Eloranta, M.L.; Ronnblom, L.; Wahren-Herlenius, M.; Syvanen, A.C.; Nordmark, G. Transcription profiling of peripheral B cells in antibody-positive primary Sjogren's syndrome reveals upregulated expression of CX3CR1 and a type I and type II interferon signature. *Scand. J. Immunol.* 2018; 87, e12662.
 17. Ciccia, F.; Guggino, G.; Zeng, M.; Thomas, R.; Ranganathan, V.; Rahman, A.; Alessandro, R.; Rizzo, A.; Saieva, L.; Macaluso, F.; et al. Pro-inflammatory CX3CR1(+) CD59(+) TL1A(+) IL-23(+) monocytes are expanded in patients with Ankylosing Spondylitis and modulate ILC3 immune functions. *Arthritis Rheumatol.* 2018.
 18. Wakita, H.; Yanagawa, T.; Kuboi, Y.; Imai, T. E6130, a Novel CX3C Chemokine Receptor 1 (CX3CR1) Modulator, Attenuates Mucosal Inflammation and Reduces CX3CR1(+) Leukocyte Tracking in Mice with Colitis. *Mol. Pharmacol.* 2017; 92, 502–509.
 19. Nanki, T.; Imai, T.; Kawai, S. Fractalkine/CX3CL1 in rheumatoid arthritis. *Mod. Rheumatol.* 2017; 27, 392–397.
 20. Tabuchi, H.; Katsurabara, T.; Mori, M.; Aoyama, M.; Obara, T.; Yasuda, N.; Kawano, T.; Imai, T.; Ieiri, I.; Kumagai, Y. Pharmacokinetics, Pharmacodynamics, and Safety of E6011, a Novel Humanized Antifractalkine (CX3CL1) Monoclonal Antibody: A Randomized, Double-Blind, Placebo-Controlled Single-Ascending-Dose Study. *J. Clin. Pharmacol.* 2018; 59.
 21. Hin H, Bird G, Fisher P et al. Coeliac disease in primary care: case finding study. *BMJ* 1999;318:164-7
 22. Gujral N, Freeman H G, Thomson A.B. Celiac disease: prevalence, diagnosis, pathogenesis and treatment. *World J Gastroenterol.* 2012;18(42):6036.
 23. Singh P. Arora A. Strand T.A. et al. Global prevalence of celiac disease: systematic review and meta-analysis. *Clin Gastroenterol Hepatol.* 2018; 16: 823-836.e2.
 24. Walker-Smith JA. Samuel Gee and the coeliac affection. In: Kumar PJ, Walker-Smith JA. editors. *Coeliac Disease: 100 Years.* Leeds: The University Printing Service at the University of Leeds. 1988;p. 1–10.
 25. Catassi C, Fabiani E, Räscher IM, The coeliac iceberg in Italy. A multicentre anti-gliadin antibodies screening for coeliac disease in school-age subjects. *Acta Paediatr Suppl.* 1996;412:29–35.
 26. Dieterich W, Ehnis T, Bauer M, Donner P, Volta U, Riecken E O, Schuppan D. Identification of tissue transglutaminase as the autoantigen of celiac disease. *Nat Med.* 1997; 3: 797-801.
 27. Bondar, C.; Araya, R.E.; Guzman, L.; Rua, E.C.; Chopita, N.; Chirido, F.G. Role of CXCR3/CXCL10 axis in immune cell recruitment into the small intestine in

- celiac disease. PLoS ONE 2014; 9, e89068.
28. Muehlhoefer, A.; Saubermann, L.J.; Gu, X.; Luedtke-Heckenkamp, K.; Xavier, R.; Blumberg, R.S.; Podolsky, D.K.; MacDermott, R.P.; Reinecker, H.C. Fractalkine is an epithelial and endothelial cell-derived chemoattractant for intraepithelial lymphocytes in the small intestinal mucosa. *J. Immunol.* 2000; 164, 3368–3376.
29. Marta Fernández-Prieto, María J. Fernández-Aceñero, Natalia López-Palacios, Andrés Bodas, Sergio Farras, David Cuevas, Virginia Pascual, M. Ángeles Cerón-Nieto, Saúl Horta-Herrera, Laura Espino-Paisán, Isabel Salazar and Concepción Núñez. CX3CL1–CX3CR1 Axis: A New Player in Coeliac Disease Pathogenesis. *Nutrients* 2019;11, 2551.